

Efficacy of Calcium Phosphosilicate as Graft Material in Bony Defects

¹Doddayapete N Umashankar, ²Kranthi S Kumar, ³R Mahesh Kumar, ⁴Narasimhamurthy Srinath, ⁵Chaithra Patil

ABSTRACT

Aim: To assess bone regeneration following calcium phosphosilicate (CPS) (NOVABONE[®]) as graft material in bony defects.

Materials and methods: A prospective study was performed with sample size of 10, where CPS putty was used in patients requiring bone grafting following enucleation of odontogenic cysts, socket preservation, sinus lift, and ridge augmentation procedure. Bone density was assessed using a gray-value histogram, Wilcoxon signed-rank test, and Friedman test.

Results: On assessing bone density, the test group has showed more mean values of bone density 128.1, 121.3, and 116.8 in the immediate, 4th, and 6th month postoperatively respectively, compared with 102.9 preoperatively with a p-value of <0.001, which is statistically significant.

Conclusion: Placement of CPS putty in bony regeneration of maxillofacial defects has shown satisfactory results. However, larger sample size, longer follow-up, and categorization of the defects are required to assess its efficacy in respective defects.

Keywords: Bone density, Bone healing, Calcium phosphosilicate, Socket preservation.

How to cite this article: Umashankar DN, Kumar KS, Kumar RM, Srinath N, Patil C. Efficacy of Calcium Phosphosilicate as Graft Material in Bony Defects. *Int J Oral Care Res* 2018;6(1):17-23.

Source of support: Nil

Conflict of interest: None

INTRODUCTION

Reconstruction of the lost bone has always presented a challenge to maxillofacial surgeons. Various attempts have been made in pursuit of gaining maximum quantitative and qualitative bone fill, simultaneously striving to minimize the morbidity.

The science of bone grafting has been employed for bone repair for hundreds of years. Bone grafting has developed into a unique scientific endeavor that is essential to many surgical disciplines. Orthopedic surgeons may be responsible for pioneering bone grafting, but since World War II, other specialists also have been extensively involved. Plastic surgeons have used bone grafting throughout the body. Foot and ankle surgeons have found multiple uses for harvesting and grafting bone in the foot and ankle. Otolaryngologists and oral and maxillofacial surgeons use bone grafts in facial reconstruction. Surgeons must be adept in bone graft harvesting and must have a thorough understanding of the biologic characteristics of the graft. Additionally, surgeons must assess final outcomes and appreciate potential complications.^{1,2}

Most of the traditional reconstructive methods are rather invasive and associated with certain amount of morbidity. The impetus of this study is to obviate donor-site morbidity. Bony defects created in maxilla and mandible, secondary to trauma, pathology, metabolic bone disorders, congenital anomalies, infection, and periodontal diseases, need to be filled with appropriate bone graft materials for esthetic and functional purposes. A multitude of bone graft materials have been used to fill such defects but all are associated with some shortcomings. Traditionally, the augmentation of bony defects is carried out using autogenous bone, allografts, alloplasts, and xenografts.

Several synthetic bone graft substitutes have been used with variable degree of success, such as bioactive glasses, aluminum oxide, calcium sulfate, calcium phosphate, alpha and beta tricalcium phosphate, synthetic hydroxyapatite. These materials may not necessarily be used solely for reconstructive procedures, but when used in right situation in combination with autografts, allografts, or other synthetics they have the potential for more desirable results.

Synthetic materials have also been developed for use as bone graft substitutes. Advantages of synthetic materials include tunable resorption rates, controlled porosity, higher mechanical strength compared with demineralized bone matrix products, ideal processing, and molding parameters. However, these materials lack inherent native growth factors due to which there is an absence of osteoinductive properties.

¹Reader, ²Assistant Professor, ³Professor, ⁴Head, ⁵Senior Lecturer

^{1,3-5}Department of Oral and Maxillofacial Surgery, Krishnadevaraya College of Dental Sciences & Hospital, Bengaluru, Karnataka, India

²Department of Dental, East Point Medical College, Bengaluru Karnataka, India

Corresponding Author: Doddayapete N Umashankar, Reader Department of Oral and Maxillofacial Surgery, Krishnadevaraya College of Dental Sciences & Hospital, Bengaluru, Karnataka India, e-mail: drumshankar1978@gmail.com

There has been improvisation in the characteristics and properties of potential synthetic bony substitutes due to the ongoing development of biomaterials. Challenge has been to assess the interface between the host and biomaterial. Alloplastic bioactive graft substitutes are a potential advance in solving this issue. Bioactive material is defined as one that will create biological response that will prevent fibrous repair at the interface, but rather lead to a bony reunion of the material and host tissue. Bioactive glass ceramics have demonstrated such biocompatibility and direct contact with bone. The first bioactive material was reported in 1971. It was a four-component oxide mixture, consisting of 45% silica oxide, 24.5% sodium, 24.5% calcium, and 6% phosphorous (US Biomaterials Corp., Alachua, Florida, USA). This product has evolved and marketed as premixed, moldable material called NOVABONE® dental material putty, which consists of four components: two bioactive phase components—a 55% standard CPS particulate, and a 14% CPS smaller particulate as well as 12% polyethylene glycol (PEG) additive phase and 19% glycerin binder phase. In dentistry, this latter putty form of CPS is designed for osseous regeneration of periodontal bony defects, filling alveolar sockets, sinuses, and augmentation of alveolar ridges.³

The purpose of this study was to evaluate clinically and radiographically CPS putty when used as a bone graft material in maxillary and mandibular bony defects secondary to trauma, pathology, and inadequate bone for implant placement.

MATERIALS AND METHODS

Study Setting

The study “Efficacy of calcium phosphosilicate as graft material in bony defects” was done in patients who reported to the Department of Oral and Maxillofacial

Surgery, Krishnadevaraya College of Dental Sciences and Hospital, Bengaluru, Karnataka, India.

Study Design

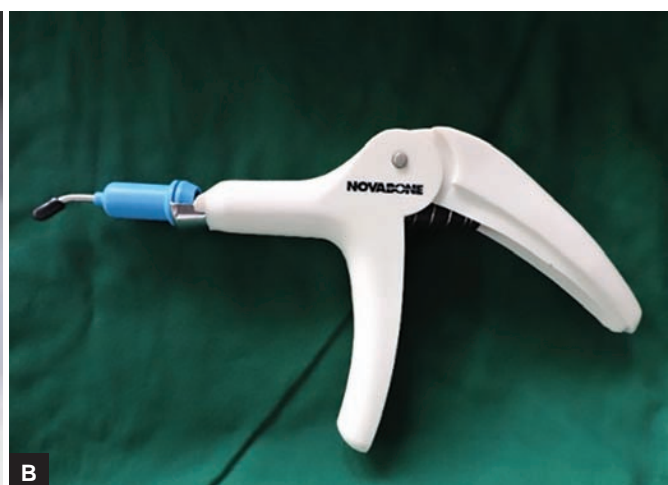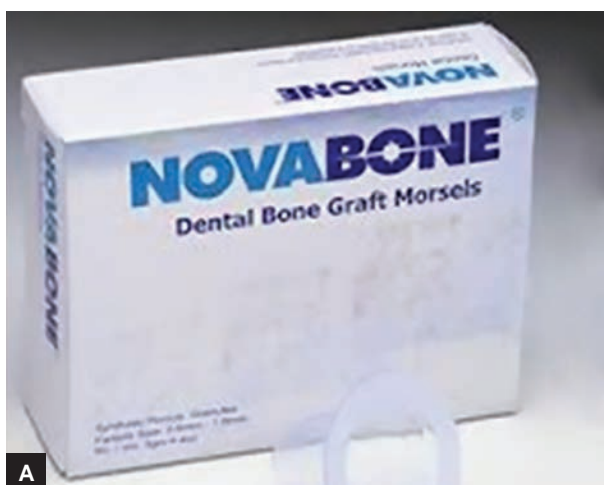Sample size was determined to be 10 patients. Patients requiring bone grafting following enucleation of odontogenic cyst, those requiring ridge augmentation, and insufficient bone for implants were chosen for the study. All patients were informed about the study and consent was taken for the same. Routine hematological investigations were carried out. Preoperative intraoral periapical view and/or panoramic radiographs (orthopantomogram) of recipient sites were taken. Calcium phosphosilicate putty was used in total of two direct sinus lift, one indirect sinus lift in the region of posterior maxillary first molar region, and in three cases of periapical cysts, which include two in mandibular region and one in maxillary cuspid region, two cases of socket preservation, one ridge augmentation, and one implant placement where there is a cortical bone defect in the maxillary central incisor region.

Materials used

- Calcium phosphosilicate putty (NOVABONE®) with dispenser (Fig. 1).
- 3-0 Polyglactin 910 suture material-Vicryl® (Ethicon Inc., Johnson and Johnson Pvt. Ltd).

Inclusion Criteria

- Age group 18 to 40 years.
- Patients with insufficient bone for the placement of implants.
- Patients requiring alveolar ridge augmentation.
- Patients with acquired bone defects created due to excision of benign tumors or cystic lesions.



Figs 1A and B: Calcium phosphosilicate putty (NOVABONE®) with dispenser

Exclusion Criteria

- Patients with habits like smoking and alcohol consumption.
- Patients with immunocompromised diseases.
- Patients with underlying metabolic or endocrine diseases.
- Patients who have recently undergone radiation therapy.

Surgical Procedure

- Procedure was done under local anesthesia. After standard skin preparation 2% lignocaine with 1:80,000 adrenaline, nerve block was given.
- Triangular/trapezoidal mucoperiosteal flap raised, cyst enucleated or tooth removal done for cyst and socket preservation respectively.
- In case of sinus lift procedure, bony window created using piezo bur, exposure of sinus membrane done, and it was lifted.

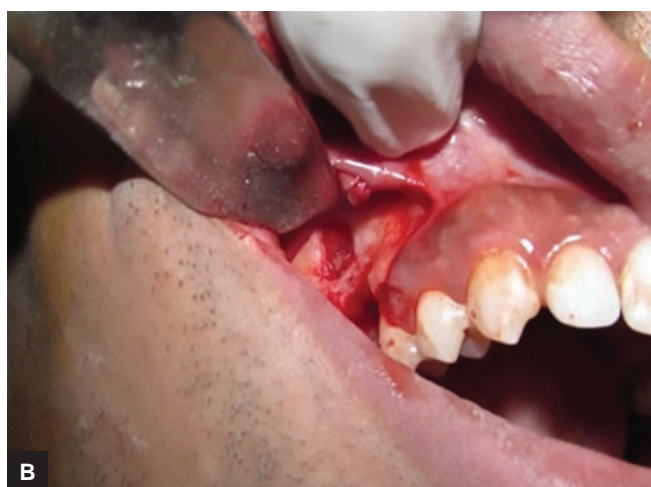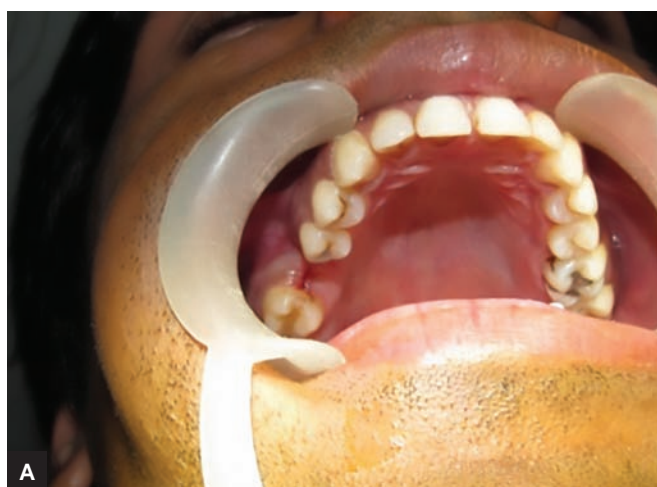- Putty graft material was injected using graft dispenser and simultaneously implant was placed after sinus lift.
- Water tight closure achieved by suturing with 3-0 Vicryl and pressure pack was given (Figs 2 to 5A).

Postoperative Procedure

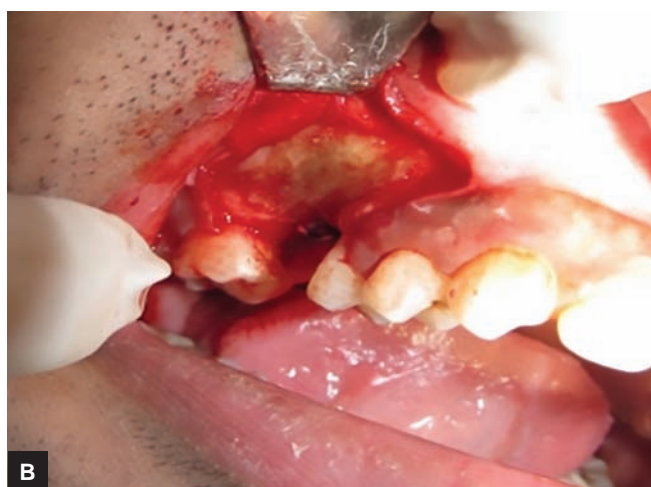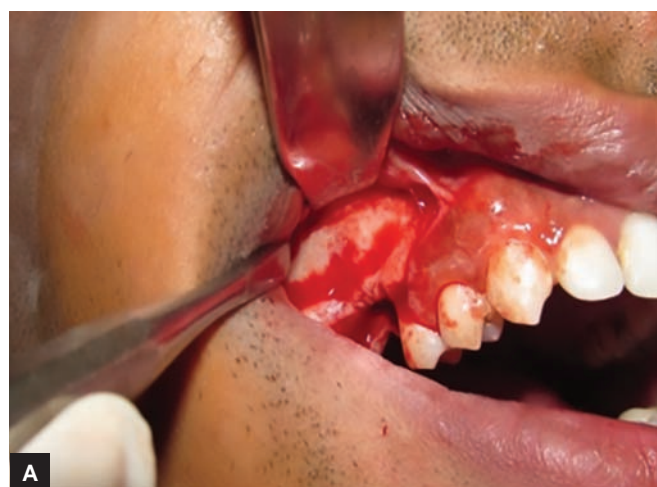- Antibiotics (Cap. Amoxicillin 500 mg + Clavulanic acid 125 mg tid for 5 days) and anti-inflammatory drugs (Tab. Diclofenac 50 mg + Paracetamol 500 mg tid for 5 days) were prescribed.
- Patients were given oral hygiene maintenance instructions.
- Patients were checked for any pain, swelling, infection at 1 week, 4 months, and 6 months postoperatively.
- Patients were evaluated for bone fill using intraoral periapical or panoramic radiographs at 4th and 6th month postoperatively (Figs 5B to 6).

CASE PHOTOGRAPHS

Direct Sinus Lift



Figs 2A and B: (A) Edentulous maxillary first molar region. (B) Sinus membrane exposed



Figs 3A and B: (A) Sinus membrane elevated and grafted. (B) Simultaneous implant placement

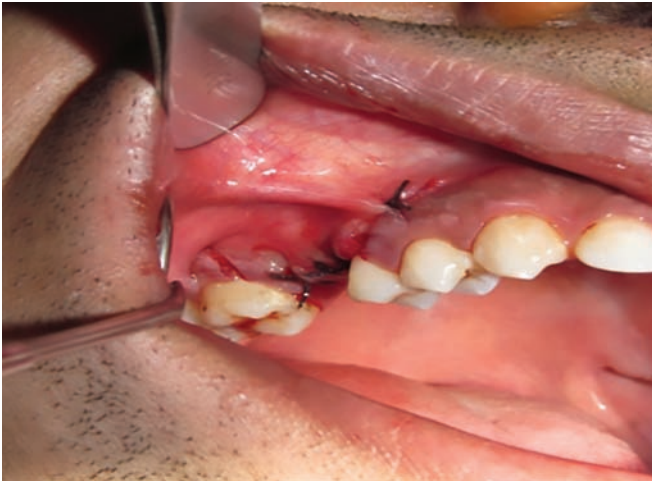

Fig. 4: Closure

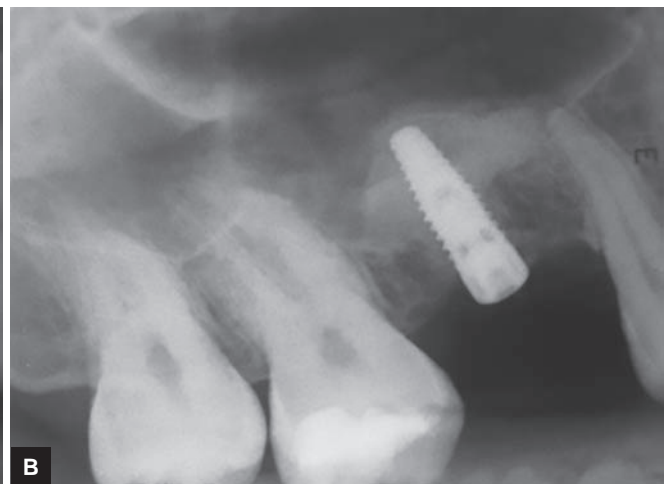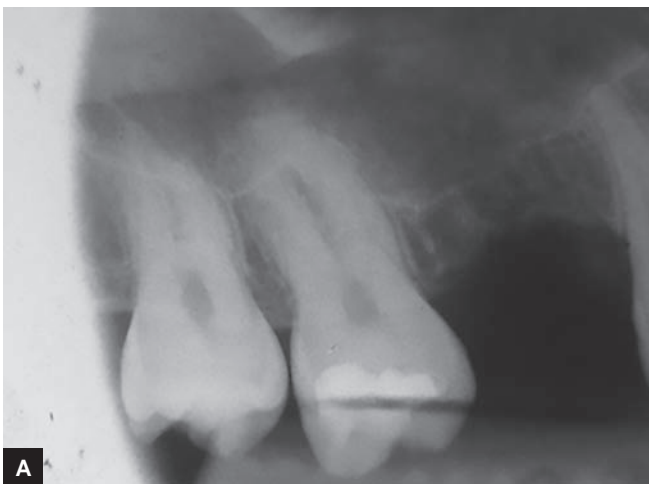
Statistical Analysis

The results of the parameter evaluated in this study are presented in percentage and averaged as [mean \pm standard deviation (SD)], and it has also been represented in tables and graphs.

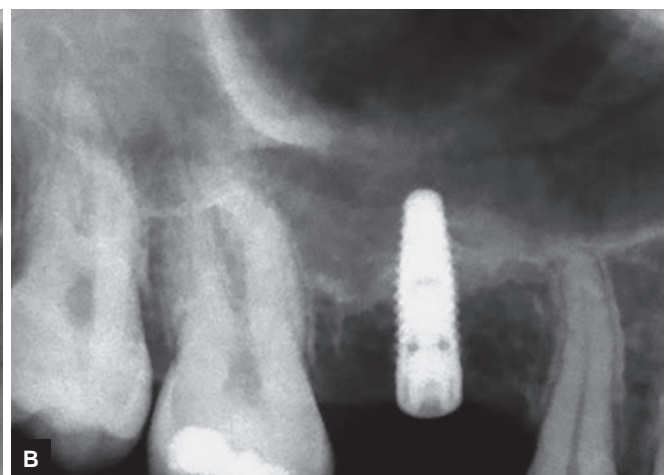
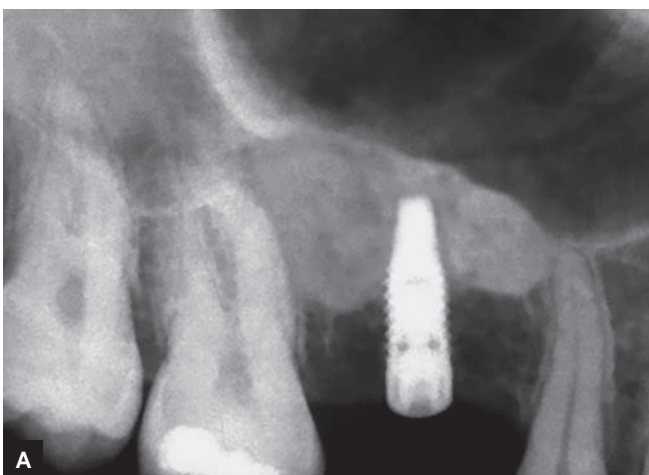
- For the comparison of mean visual analog scale (VAS) scores in maxilla and mandible after 1 week of postoperative period, Mann–Whitney test is used.
- To find out medians of which group differ significantly, Mann–Whitney U test is performed.
- For intergroup comparison between preoperative values, 4th month, 6th month, postoperative, and control values, Wilcoxon matched pair and signed rank test is used.
- Comparison of mean grayscale scores within subjects in postoperative site at different time intervals was using Friedman test.

Radiographic Evaluation of Bone Density

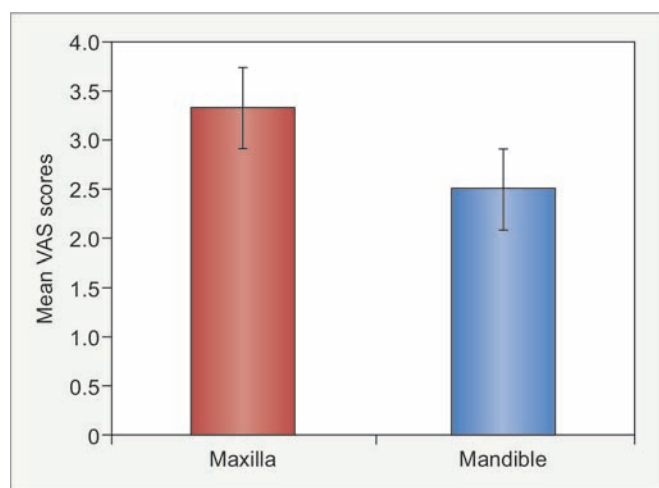
The images were digitized using a scanner (Epson Expression 1680 pro, Seiko Epson Corp, Tokyo, Japan) and processed with the Adobe Photoshop 7.0 software (Adobe Systems Inc.). To compare the same patients' radiographs taken at different times, contrast matching was used. The radiolucency of adjacent sound bone was used as control group.



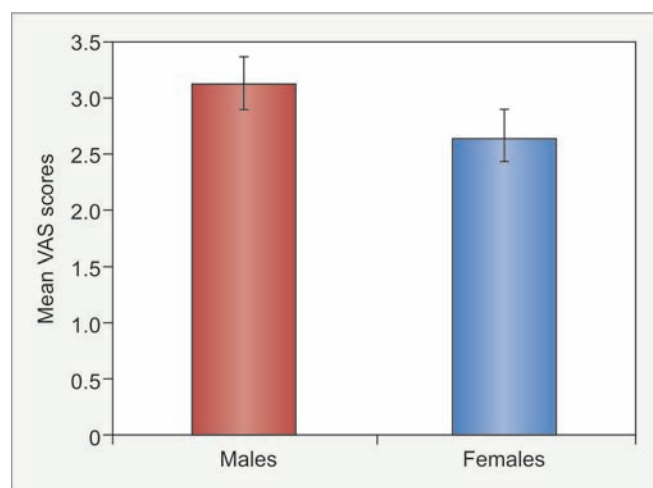
Figs 5A and B: (A) Preoperative radiograph. (B) Immediate postoperative



Figs 6A and B: (A) Postoperative 4th month. (B) Postoperative 6th month



Graph 1: Comparison of mean VAS scores for pain during 1 week of postoperative period in different sites



Graph 2: Gender-wise comparison of mean VAS scores for pain during 1 week of postoperative period

The control region and the defect were defined through a grayscale of 255 tonalities using gray-level histograms. A single examiner demarcated the outline of the lesion. The control regions from radiographs taken at different times were matched, and the mean gray-level values of the regions of interests were calculated and then compared with each other.

RESULTS

The present study was done in the Department of Oral and Maxillofacial Surgery, Krishnadevaraya College of Dental Sciences and Hospital, Bengaluru.

Calcium phosphosilicate putty was used in three sinus lift cases, filling of defect after enucleation of cysts, two cases of socket preservation following removal of impacted teeth, and one case of ridge augmentation in mandibular anterior region, and one case implant placement with buccal cortical bone defect.

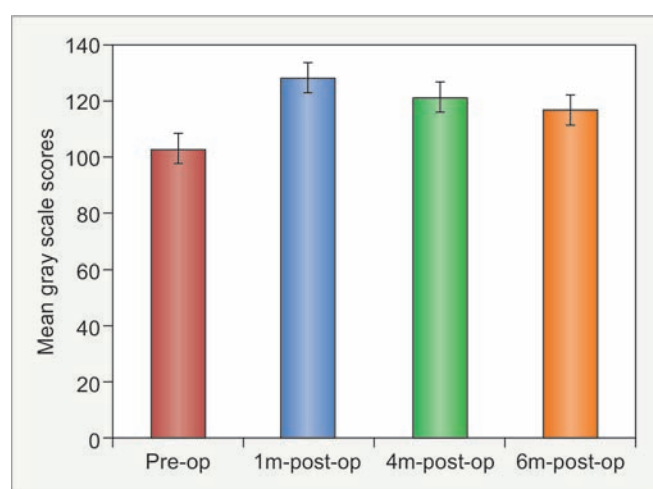
Patients were in the age group of 16 to 52 years with 7 males and 3 females. All patients were assessed clinically and radiologically. Clinically, patients were checked for pain (VAS), swelling, and infection at 1 week, 4 months, and 6 months after postoperatively. The radiographic assessment of osseous defect was done preoperatively, immediate postoperative, 4th month, and 6th month postoperatively. Changes in bone density were evaluated using gray-value histogram.

Age Distribution of Patients

Mean age group of the male patients was 27.1 years with SD of 8.2 and that of females was 44 years with SD of 8.5.

Gender Distribution of Patients

Seven of the patients (70%) were males and three patients (30%) were females.



Graph 3: Comparison of mean gray-scale scores within subjects in postoperative site at different time intervals

Assessment of Complications

Pertaining to comparison of postoperative pain assessed in the maxilla and mandible by VAS, 1 week postoperatively, mean value was 0.83 and p-value was 0.39. Gender-wise pain assessment showed the mean value of 0.47 and p-value of 0.69. The result was statistically significant ($p = 0.01$) (Graphs 1 and 2).

The presence of swelling and infection was assessed in the 1st week, 4th month, and 6th month postoperatively; here swelling was present only in the first month and no infection was seen postoperatively.

Assessment of Bone Density

The bone density of the grafted site was assessed at various time intervals, preoperatively, immediate postoperative, 1st, 4th, and 6th month postoperatively using gray-value histogram, Wilcoxon signed rank test, and Friedman test (Graph 3). Statistically tabulated results are shown in Table 1.

Table 1: Comparison of mean grayscale scores within subjects in postoperative site at different time intervals using Friedman Test

Time period	n	Mean	SD	Min	Max	χ^2 value	p-value
Preoperative	10	102.9	11.229	90	119	20.939	<0.001*
1st month postoperative	10	128.1	19.913	98	160		
4th month postoperative	10	121.3	19.334	80	145		
6th month postoperative	10	116.8	15.462	89	135		

*Statistically significant

DISCUSSION

Loss of bone can occur as part of physiological process or it can occur secondary to trauma, pathology, metabolic bone disorders, congenital anomalies, or due to transalveolar extractions, prolonged edentulous and periodontal diseases as in the maxilla and mandible.

If the loss of bone hinders the function and esthetics in a patient, it becomes imperative to restore the lost bone. Bone is the second most transplanted tissue in the world and the immense need for bone grafts and substitutes has been forecasted.

Bone grafting is a dynamic process. In the past, the success of a bone graft was measured by its ability to withstand the stresses applied to it. Today, bone grafts are considered more as biologic structures. A successful bone graft is applied, becomes incorporated, revascularizes, and assumes the form desired. There are several different types of bone grafts available. They are generally classified based on the donor and structure types. Donor types include autograft, allograft, isograft, xenograft, and synthetic bone grafts. Bone grafts also differ based on their structure type, which correlates with their indications for application. Structure types include cortical, cancellous, and cortico-cancellous.

The ongoing development of biomaterials has improved the characteristics and properties of potential synthetic bony substitutes. In our study we have used CPS putty, which is a bioactive material.

Calcium Phosphosilicate Putty (NOVABONE®)

Calcium phosphosilicate (NOVABONE) dental putty is a new, next-generation CPS bone graft material built from a bioactive glass platform with additives like PEG and glycerin to improve handling and efficacy. The particulate and binder are provided premixed as a pliable cohesive material. On implantation, the binder is absorbed to permit tissue infiltration between the bioglass particles. The particles are slowly absorbed and replaced by new bone tissue during the healing process. This osteostimulation results in new bone formation throughout the grafted site at rates faster than those seen with other synthetics.

The putty format allows easier manipulation due to its format and eliminates the need for any preparation prior to placement. This CPS putty is available in various delivery systems as shells, cartridges, and syringes of various sizes with benefits of consistent, reliable bone regeneration. Built on a CPS platform, NB putty demonstrates superior performance characteristics that are a result of multiple physical and chemical interactions: "Osteostimulation." Putty has been approved by Food and Drug Administration and CE dental indications in 2007. It was the first synthetic putty that required no handling or manipulation and the first to be available in a significantly simplified cartridge delivery system. Calcium phosphosilicate putty minimizes graft wastage and reduces chair-side time.

Unlike other synthetic grafts that are bioinert, CPS putty belongs to the class of bioactive regenerative materials that not only act as an osteoconductive scaffold but also interacts with the surrounding tissues and imparts an osteostimulatory effect. Moreover, CPS putty is not osteoinductive but a number of *in vivo* studies have demonstrated an accelerated bone formation with CPS particles. Also, the viability and proliferation potential of osteoblasts has been shown to be exemplified in the presence of CPS particles. These CPS particles contain an increased osteocalcin and alkaline phosphatase levels providing a favorable site for bone formation.

Osteostimulation is an active process, and CPS dental putty acts as a bone matrix and encourages differentiation of new bone cells at the site. Hence, bone regeneration is hastened by the action of osteostimulation and osteoconduction with simultaneously increasing the resorption rate of the graft material.

Composition

The CPS putty is composed of a bimodal particle distribution of CPS (active ingredient), with PEG as an additive and glycerin as the binder. The volume of the active ingredient is approximately 70%. The components are premixed, and the putty is delivered in a ready-to-use state. Both PEG and glycerin are water soluble and are engineered to be absorbed from the site in 3 to 5 days. The putty is tan in color after sterilization.

Indications⁴

The CPS putty can be used for all maxillofacial defects that require bone grafting which includes:

- Immediate implant surgeries
- Ridge augmentations
- Sinus elevations
- Cystic defects—apicoectomies
- Craniomaxillofacial defects
- Fenestration and dehiscence defects

Advantages of the CPS Putty⁵

- Ideal for minimally invasive surgeries, hard to access defects, immediate implant surgeries, osteotome sinus surgeries, etc.
- Unique to CPS putty, osteostimulation increases the rate of bone formation.
- Putty will not washout from the graft site during irrigation and suction.
- During manipulation CPS putty does not adhere to surgical gloves or instruments.
- CPS putty has no risk of antigenic response or disease transmission.
- CPS putty appears radiodense on the radiograph.
- It is stable at room temperatures (25°C) and does not require any refrigeration.

Fate of CPS Putty Graft

Upon implantation, clinically the binder gets absorbed within 24 to 72 hours creating a three-dimensional porous scaffold that facilitates active movement of blood and tissue fluids through the matrix. There is an initial burst of calcium and phosphate ions, which is provided by the interaction of small CPS particles with blood. Numerous calcium phosphate nodules are formed due to this interaction that mature individually to form bone throughout the defect. Subsequently, the larger particles react and continue the process of bone regeneration.

In our study, CPS putty was used in three sinus lift cases, two cases of socket preservation following removal of impacted teeth, one case of ridge augmentation in mandibular anterior region, one case of implant placement with buccal cortical bone defect, and three cases of filling of defect after enucleation of cysts.

Bone density analysis suggests that there was steady increase in bony density for 6 months. All the cases have shown remarkable increase in bony density throughout the healing period. Fourth and sixth month follow-up shows resorption of graft material and appearance normal bone with regular trabeculae pattern, without any peri-implantitis in sinus lift case. Uneventful healing without any dehiscence and material exposure was noted in cyst enucleated and socket preservation case. Gray values show bone density of more or less equal to control region.

CONCLUSION

Conclusions drawn from our study are as follows:

- Calcium phosphosilicate putty is a novel material, which has the potential for bone regeneration. With appropriate case selection, it can be used as an alternative to the conventional strategies of bone regeneration, such as use of autologous bone, allografts, xenografts, etc.
- The putty can be easily shaped and contoured which facilitated us to use it in various intraoral defects, such as cystic cavities, socket preservation, ridge augmentation, and insufficient bone for implant placement.
- One great advantage of the material was that its stability on the bone and the cohesive structure prevent its dislodgment.
- Bioactive glass is a mucosa-friendly material and graft dehiscence was nil in all the cases.
- The osteoconductive property of the bioactive glass helps in gradual bone formation which was evident in all the cases.
- Although superior mechanical properties of bioactive glass have been well documented in literature, it cannot act as a load-bearing construct, which precludes its use in large osseous reconstruction.
- Longer degradation time of the material entails that long-term follow-up should be maintained to assess clinical and radiological outcomes.

Since we got a very good success rate in 6-month follow-up, we conclude that the use of COS putty in bony regeneration of maxillofacial defects has satisfactory results. However, larger sample size, longer follow-up, and categorization of the defects are required to assess its efficacy in respective defects. Moreover, use of an osteoinductive agent along with putty graft and comparison of the putty graft with a control group, such as that with an autogenous bone will provide more assenting result.

REFERENCES

1. Kher U, Mazor Z, Stanitsas P, Kotsakis GA. Implants placed simultaneously with lateral window sinus augmentation using a putty alloplastic bone substitute for increased primary implant stability: a retrospective study. *Implant Dent* 2014 Aug;23(4):496-501.
2. Kher U, Shanbhag S. One-stage transalveolar vs. lateral maxillary sinus augmentation in severely resorbed sites using calcium phosphosilicate putty: a proof-of-concept study. *Clin Oral Implant Res* 2014;25(10).
3. Jamjoom A, Cohen R. Grafts for ridge preservation. *J Funct Biomater* 2015 Aug;6(3):833-848.
4. Kotsakis G, Chrepa V, Katta S. Practical application of the newly introduced natural bone regeneration (NBR) concept utilizing alloplastic putty. *Int J Oral Implantol Clin Res* 2011 Sep-Dec;2(3):145-149.
5. Salama M, Lanka M, Kurtzman G. Extraction of an impacted maxillary canine with immediate implant placement. *Inside Dent* 2012 Mar:64-67.